

Preserve teeth, preserve patients

Dr Torsten Neuber gives an overview of the trends in endodontics and the choices available to general dentists today to achieve high success rates in endodontic cases.

In the past 15 years the field of endodontics has experienced a meteoric rise from its former understated position to a high-tech discipline. Today, it is one of the most innovative domains in dentistry.

In a world defined by globalization and deregulation, dentists are under increased pressure to be successful economically, independently of the social healthcare systems of the countries they practice in. This means dental practices experience tough competition and survival is ensured by strategic planning, such as defining target groups and identifying market niches.

Patients vote with their feet

Within the scope of worldwide networks and multi-media sources our patients are improving their knowledge. The possibilities of conservative dentistry are becoming known to ever-growing patient circles. Despite increasing sales of implants, many patients prefer to conserve their teeth wherever possible, making technically ambitious and costly prosthetic restorations less desirable.

This is the opportunity for dentists who are skilled in preserving teeth durably by means of good endodontic practice to establish a good reputation and gain new patients by word of mouth, with obvious financial benefits.

In the eyes of the patient, a dentist's competence begins with transparent information. The patient should be informed about different therapeutic alternatives including a relevant risk to benefit profile, which translates to a cost to benefit ratio. In the end, it is the patient, a mature, educated and therefore equal partner, who makes the therapeutic choice.

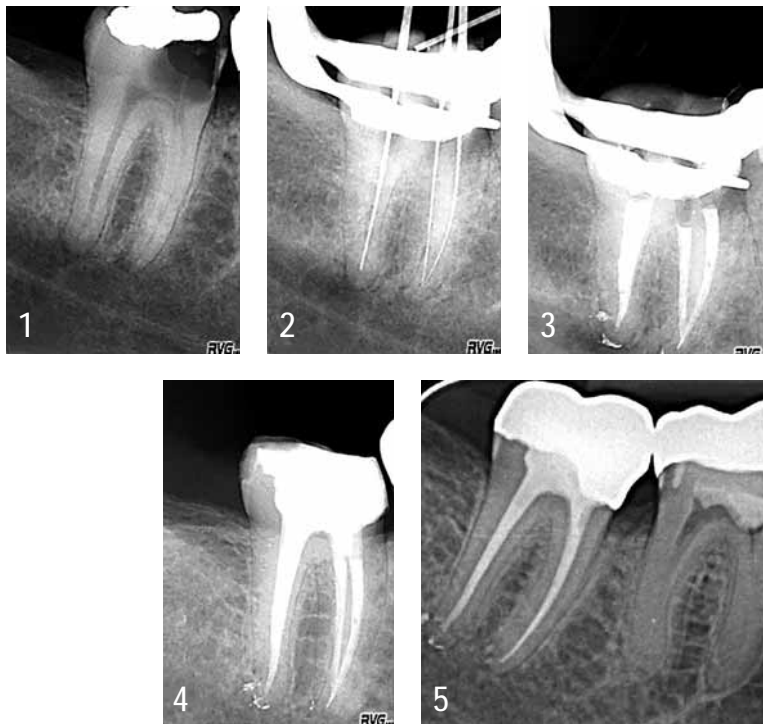

Figure 1: Initial radiograph, caries profunda, strong defect in substance and periradicular distal periodontitis.

Figure 2: Measuring radiograph. **Figure 3:** Control of root filling immediately after root filling. **Figure 4:** Control of root filling after 13 months, prior to crown placement. **Figure 5:** Control of root filling after 21 months (with crown placement done).

Treatment requirements

For the most part, primary endodontic treatment can be managed by a committed general dentist with very good prognoses. In these cases, high-tech equipment is not as important as keeping to a standardized treatment protocol. Maintaining aseptic conditions, such as the complete elimination of caries, pre-endodontic restoration, and using a rubber dam are a must.

Central to the treatment is the access cavity, including the preparation of the entire root canal system and the complete preparation and cleaning (the instrument gives form while the irrigation solution cleans). Another essential requirement is the tight three-dimensional seal of the root canal system including the post-endodontic restoration.

Toolkit for the general dentist

The market offers a diversity of devices and instruments today. Affordable investments in the endodontic practice, can result in a significant increase in treatment quality and comfort for the dentist and patients alike. After a short period of becoming acquainted with the different systems, the expenses will soon be written off and profit will be made.

Fracture resistant nickel titanium instruments used in torque-controlled motors provide better shaping and more efficient irrigation, thus reducing bacteria. Preparation itself becomes less arduous and tiring (and in most cases, also faster) for the dentist than hand preparation. File systems, including few but very effective instruments, like a basic sequence and additional files for individual apical preparation are user-friendly due to their manageability.

The congruent shapes of preparation instruments and gutta-percha points provide better and faster obturation results. Even tighter and three-dimensional root canal fillings can be achieved with vertical condensation of warm gutta-percha.

Precise and reproducible electronic length determination supports the patient's wish for less radiation exposure, provides the dentist with more safety (preventing over-instrumentation) and gives to both the gift of more time.

Torque -controlled motors with integrated electronic length measuring function combine the advantages of rotary preparation and electronic length determination. If a tooth is severely damaged, a once-off adhesive restoration immediately after obturation is recommended in order to avoid re-infection. Bacteria-proof seals and restoration of the statics, providing dentin-like elasticity, are easily achieved with glass fibre posts. Both patients and dentists benefit from the time saved through this. Furthermore, the business stays in the practice and does not go to the laboratory.

Guaranteed success

In certain cases, every dentist will reach his or her limits. Failures cannot be avoided, but they can certainly be minimized. The keyword for success is case selection. The dentist should be self-critical of the capabilities and limits of the equipment. The level of difficulty of an endodontic treatment can be evaluated objectively using specific parameters: accessibility of the tooth, radiographical indication of obliterations, curvatures, additional canal systems, uncompleted growth of the root, resorptive or periradicular alterations at the apex and revisions.

Referral to a specialist equipped with expertise and highly specialized equipment like a dental microscope and ultrasound, is in no case a sign of weakness or incompetence on the part of the dentist, but rather a sign of

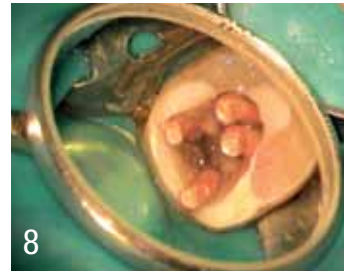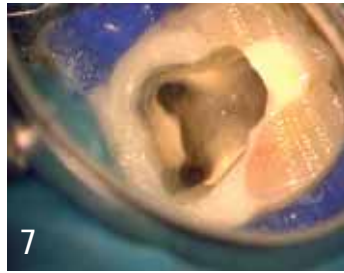
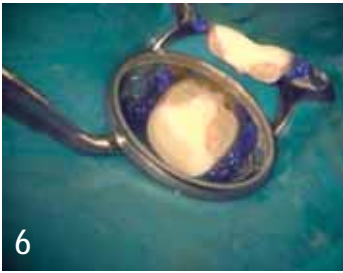


Figure 6: Pre-endodontic restoration.

Figure 7: Trepanation.

Figure 8: 4 canals filled with gutta-percha points.

professionalism and responsibility. Patients will come to recognise this trait, placing the general dentist in higher esteem.

It is crucial that a good relationship is established between the general dentist and specialist, allowing for a clear understanding of the treatment mandate and the infrastructure of information flow, radiographs, patient instructions, re-referral to general practitioner, medical report, further therapeutic recommendations.

Conclusion

Predictable, successful and safe endodontic treatments are no longer accidental. Adequate case selection and a standardized treatment protocol allows the general dentist to maintain financially manageable equipment (e.g. no need of microscope, etc.) while gaining successful case prognoses. The dentist who is able to convince patients that by not extracting unnecessarily and trying the utmost possible to permanently preserve teeth, creates his or her own practice marketing instrument. Tooth preservation by endodontic treatment is a means to acquire patients and their loyalty. Last but not least it satisfies the practitioner.

“The keyword for success is case selection.”

About the author



Dr Torsten Neuber completed his dental education at Westphalian Wilhelms University and set up a private practice in Munster, Germany. After further training and certification in endodontics, he established a referral practice in 2002 and became a founding and board member of the Association of German Certified Endodontologists (VDZE) and the

German Endodontic Association. He is also a board member of Working Group Traumatology and Endodontology (AGET) and a member of European Society of Endodontology (ESE). He lectures nationally and internationally on endodontic topics and has a joint practice with Dr Anselm Brune in Munster.

Send your comments and questions to editorial@dpreeurope.com